



PATIENT

Peanut Girish

SPECIES

Canine

BREED

Lab mix

SEX

FS

AGE

8

WEIGHT

29

INTERPRETED BY

R. McKenzie Daniel,
DVM, DABVP
(Canine and Feline)

IMAGING PERFORMED BY

Jenn

HOSPITAL NAME

Rockaway Animal
Hospital

REFERRING VET

Dr Maniar

INVOICE

23149

DATE

12/8/2025

PRESENTING CLINICAL SIGNS

vomiting profusely lethargic

ULTRASONOGRAPHIC EXAMINATION OF THE ABDOMEN

Urinary System

The urinary bladder, trigone, cystourethral junction, and visible pelvic urethra to a depth of 2 cm exhibited normal thickness and tone. Anechoic urine was present in the lumen with no evidence of urine/lumen sediment, mineral, or calculi. The ureteral papillae were normal. The ureters were not visible which is normal. No evidence of inflammatory or neoplastic changes was noted.

Normal size and margination were present in the kidneys. A normal 1:3 cortex / medulla ratio and normal corticomedullary definition were maintained. The echogenicity of the cortex was similar to or slightly less than normal liver parenchyma while the medulla echogenicity was hypoechoic to the cortex with no evidence of pelvic dilation. The left kidney measured 6.0 cm in length. The right kidney measured 6.0 cm in length.

The area of the aortic trifurcation was free of pathology.

Adrenal Glands

The left adrenal gland was uniform in size and contour with a uniformly hypoechoic parenchyma. The left adrenal gland measured 0.65 cm width at the caudal pole. The right adrenal gland was uniform in size and contour with a uniformly hypoechoic parenchyma. The right adrenal gland measured 0.82 cm width at the caudal pole.

Spleen

The spleen exhibited a finely textured and homogenous parenchyma which was hyperechoic to the liver and renal cortical parenchyma. The capsule was smooth and regular without apparent expansion. The splenic vasculature at the hilus was normal in volume with no evidence of congestion or thrombosis. Acute to chronic inflammatory, neoplastic, or benign parenchyma changes were not noted.

Liver/Gallbladder

The liver was subjectively normal in size, structure, and contour. The liver parenchyma was uniform and hypoechoic to the spleen with a mild coarse echotexture. Normal vascular volume. The hepatic and portal vasculature were normal in appearance without signs of congestion. The gallbladder was non-distended in size with thin walls and primarily anechoic luminal content. The cystic and common bile ducts were normal.

Gastrointestinal

The visualized stomach presented intact wall layering with mild prominent mucosa. The stomach contained a mild to moderate amount of retained anechoic fluid. Definitive obstruction to pyloric outflow was not overtly visualized. Mildly thickened gastric mucosa and stomach wall measured 0.7 cm in width.



PATIENT

Peanut Girish

The small intestine presented intact wall layering with 1:3 muscularis/mucosa ratio. The lumen of the small intestine was empty with no signs of mechanical/metabolic ileus, obstruction or foreign material.

Normal visible colon wall layers were present with apparent formed feces in lumen.

SPECIES

Pancreas

Canine

The area of the pancreas was sonographically normal.

Free Abdomen

BREED

No omental masses, overt lymphadenopathy or peritoneal effusion was present.

Lab mix

ULTRASONOGRAPHIC FINDINGS

SEX

Primary

FS

- Hypomotile gastritis
- Sonographically normal empty small intestine
- Normal area of pancreas

AGE

8

INTERPRETATION OF THE FINDINGS & FURTHER RECOMMENDATIONS

No overt visualized mechanical gastrointestinal obstructive criteria i.e. foreign body, mass etc. Gastrointestinal support and empirical therapy for hypomotile gastritis with clinical monitoring is recommended. Sonographic reassessment with consideration for upper gastrointestinal endoscopy indicated if continued or progressive gastrointestinal signs. Although considered less likely given normal adrenal presentation, a screening cortisol level to rule out Addison's disease is recommended.

WEIGHT

29

INTERPRETED BY

R. McKenzie Daniel,
DVM, DABVP
(Canine and Feline)

IMAGING PERFORMED BY

Jenn

HOSPITAL NAME

Rockaway Animal
Hospital

REFERRING VET

Dr Maniar

INVOICE

23149

DATE

12/8/2025



PATIENT

Peanut Girish

SPECIES

Canine

BREED

Lab mix

SEX

FS

AGE

8

WEIGHT

29

INTERPRETED BY

R. McKenzie Daniel,
DVM, DABVP
(Canine and Feline)

IMAGING PERFORMED BY

Jenn

HOSPITAL NAME

Rockaway Animal
Hospital

REFERRING VET

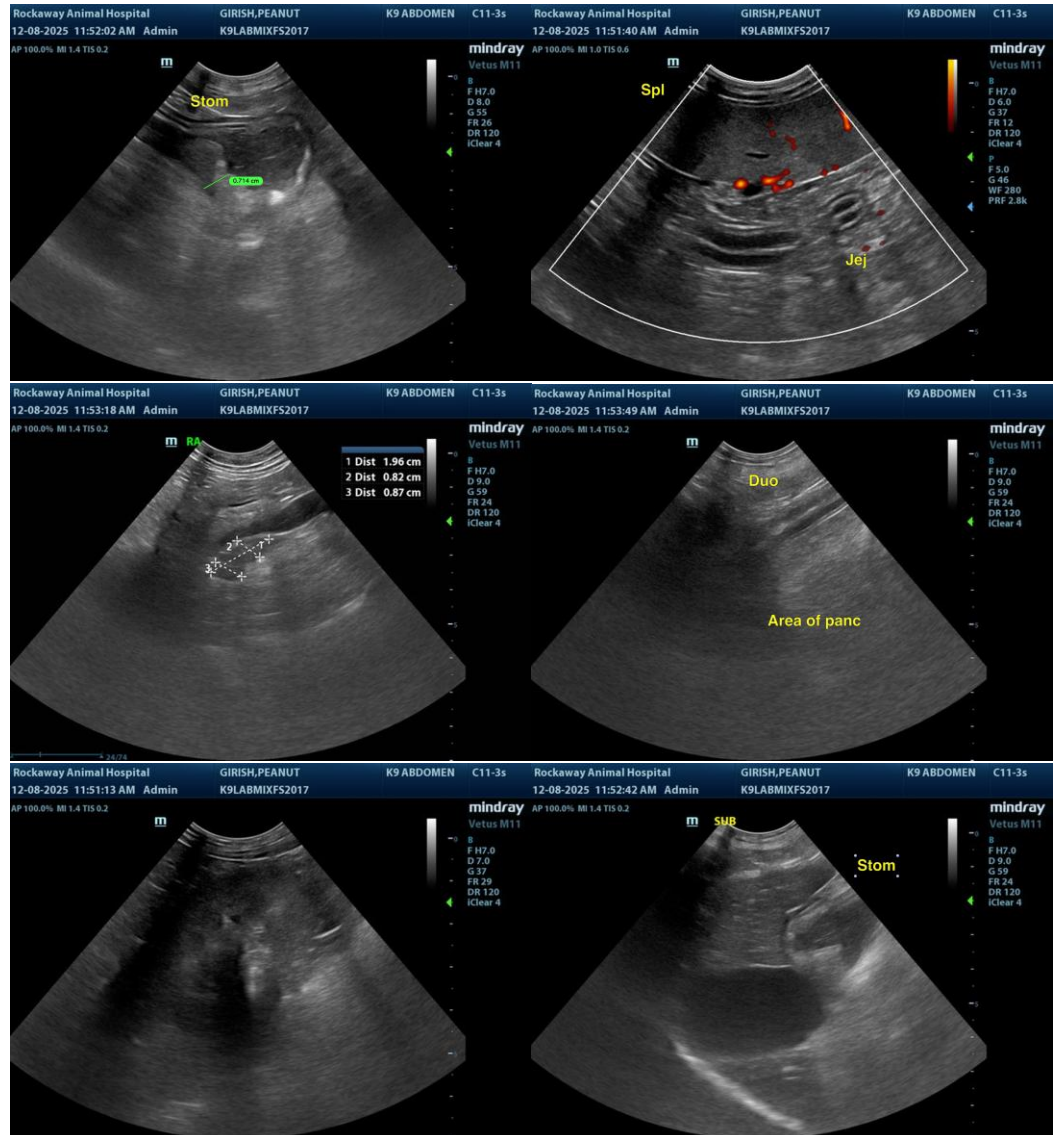
Dr Maniar

INVOICE

23149

DATE

12/8/2025





PATIENT

Peanut Girish

SPECIES

Canine

BREED

Lab mix

SEX

FS

AGE

8

WEIGHT

29

INTERPRETED BY

R. McKenzie Daniel,
DVM, DABVP
(Canine and Feline)

IMAGING PERFORMED BY

Jenn

HOSPITAL NAME

Rockaway Animal
Hospital

REFERRING VET

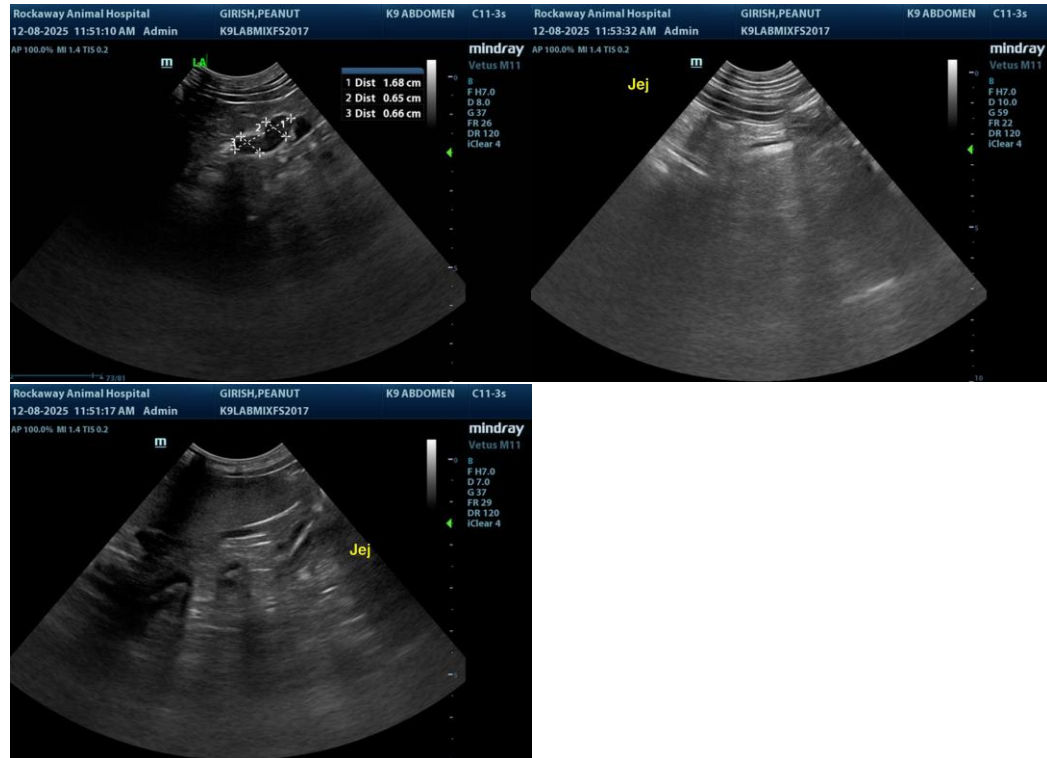
Dr Maniar

INVOICE

23149

DATE

12/8/2025



The information and recommendations provided are based on the images presented by the referring veterinarian/sonographer. No evaluation can be communicated regarding pathology that was not visible in the image/video clips provided.

Thank you for this referral. If the clinical or image interpretation does not parallel your findings or if I can be of any further assistance, please contact me.

R. McKenzie Daniel, DVM, DABVP (Canine/Feline Practice)
info@sonopath.com